

CASE 1 (Dermatomyositis): Initial Presentation

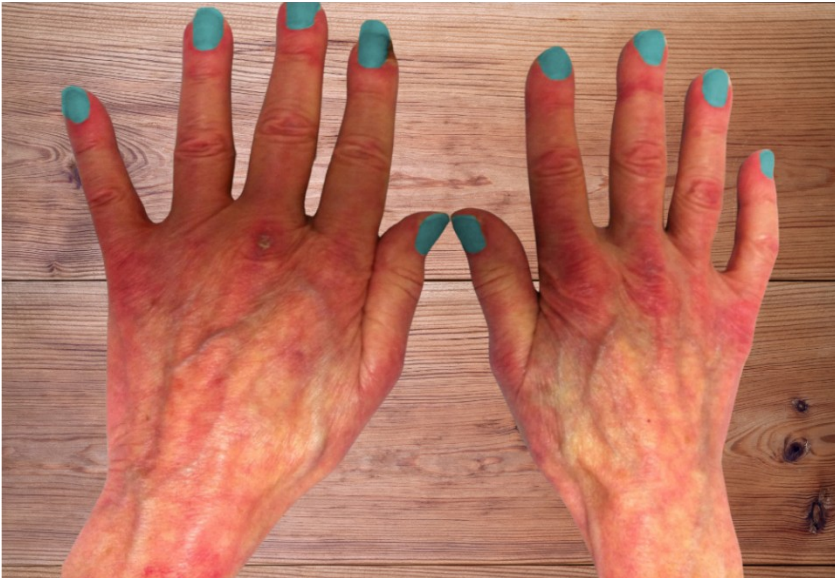A 46-year-old Caucasian female presented with complaints of fatigue and progressive muscle weakness in the proximal extremities (primarily in the arms and thighs) for the past 4 weeks. She felt tired and found it challenging to go about routine activities in the last few weeks. However, she did not report fever or weight loss. The weakness was profound and lately had increased to such an extent that she needed help for bathing and toileting.

In addition, she recently noticed a slight change in her voice and mild dysphagia with solid foods. She also complained of worsening dyspnea on exertion and non-productive cough for the last two weeks, but not requiring supplementary oxygen. She denies any joint pain or swelling but has mild myalgias. She did not report Raynaud's, joint pain, and gastrointestinal symptoms; otherwise, the rest of the review of system was unrevealing.

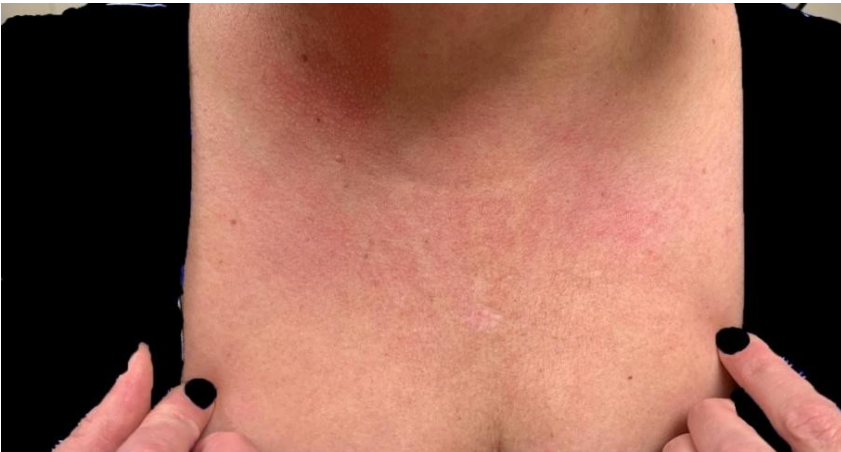Examination revealed several rashes developing in last 2-3 weeks, with dark red erythematous papules and cutaneous ulcer on the dorsum surface of the hands. She also has a mild to moderate red rash on the upper chest and upper back, as well as mild pink rash over both elbows with scales and mild erosion. Periungual erythema was observed with abnormal nail fold capillaries. Rest of the body areas were free of rashes and there is no hair loss or calcinosis or poikiloderma. There was a bilateral late inspiratory crackle sound in the lung bases upon auscultation. Musculoskeletal examination confirmed profound proximal bilateral symmetric muscle weakness with the patient is only able to hold and sustain against gravity in iliopsoas and deltoid, able to hold against only mild pressure by the examiner in gluteus medius and maximus, mild to moderate pressure in neck flexor, moderate to strong pressure in neck extensors, biceps, triceps, quadriceps and hamstring, but the rest of the muscle and systemic examination showed no significant abnormalities. There are no cardiac abnormalities seen on examination.

Laboratory Investigations showed elevated CK (900 IU/L) and ferritin (1010 mcg/L). HRCT of the chest was suggestive of Interstitial Lung Disease (ILD) with bi-basal ground-glass opacities and linear reticulations suggestive of moderate Non-Specific Interstitial Pneumonia (NSIP) involving 25-30% of the lung fields scanned with Forced Vital Capacity (FVC) of 70% (normal FEV1/FVC ratio). EMG also showed evidence of myopathy; however, a muscle biopsy was not performed.

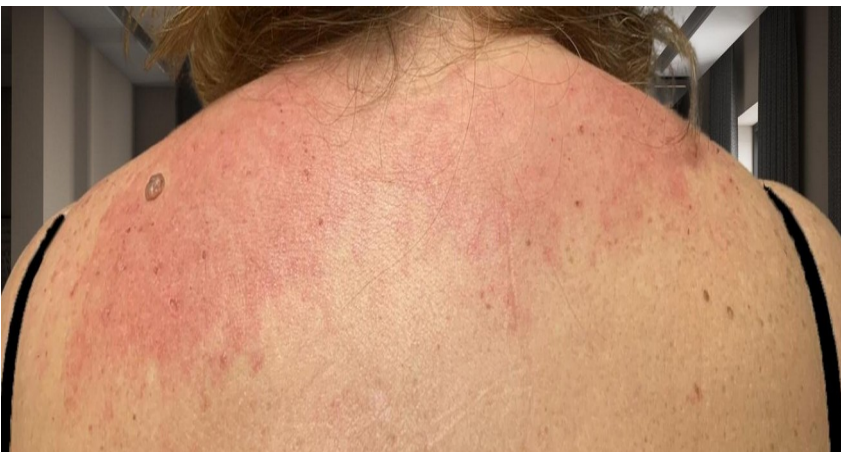Representative Rash Images of Patient:



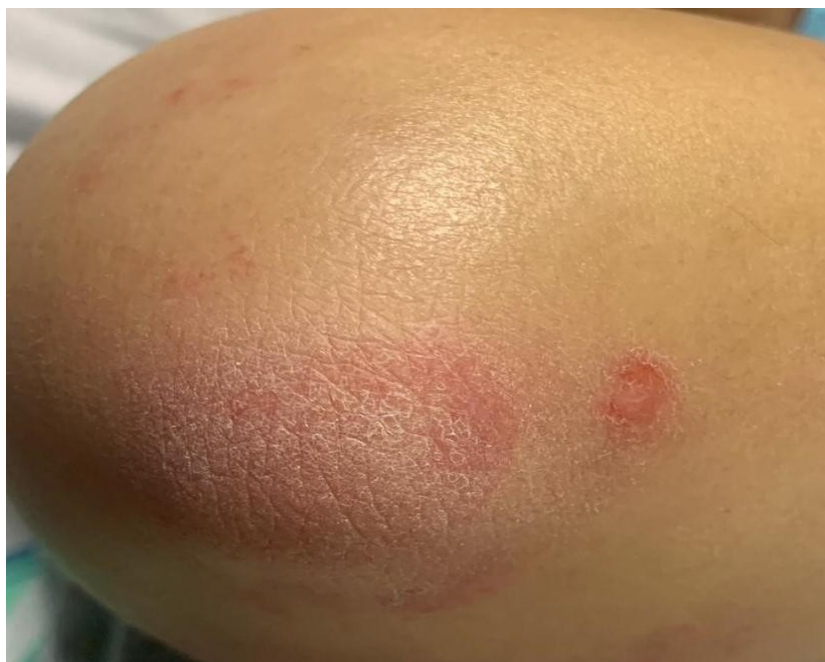Dorsum of hand



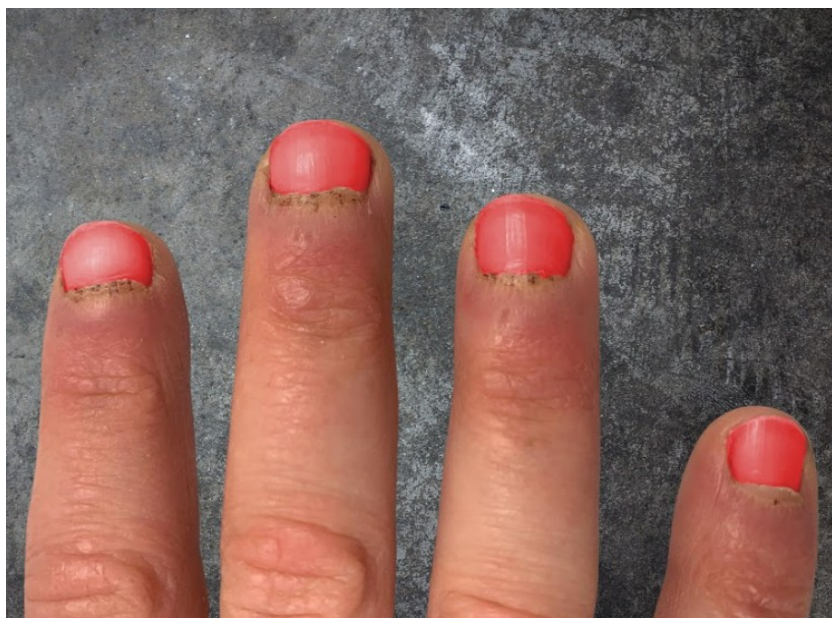
Upper chest (V area of neck)



Upper back and Shoulder



Elbow



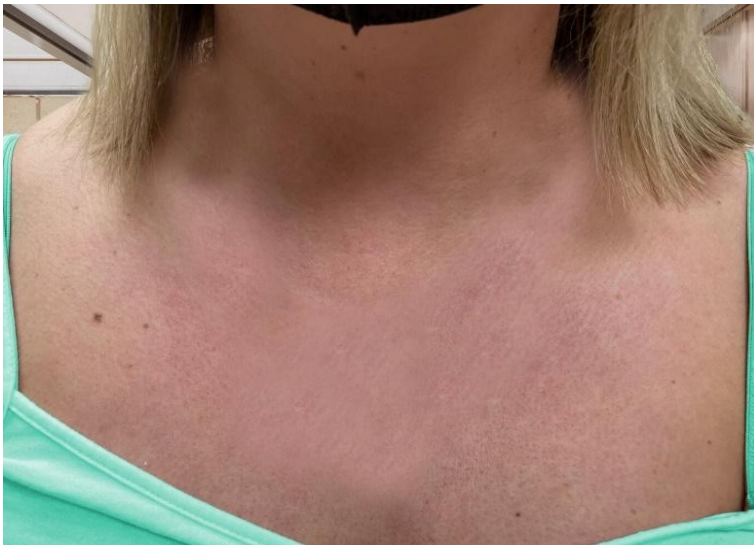Periungual

CASE 1 (Dermatomyositis): Follow up visit

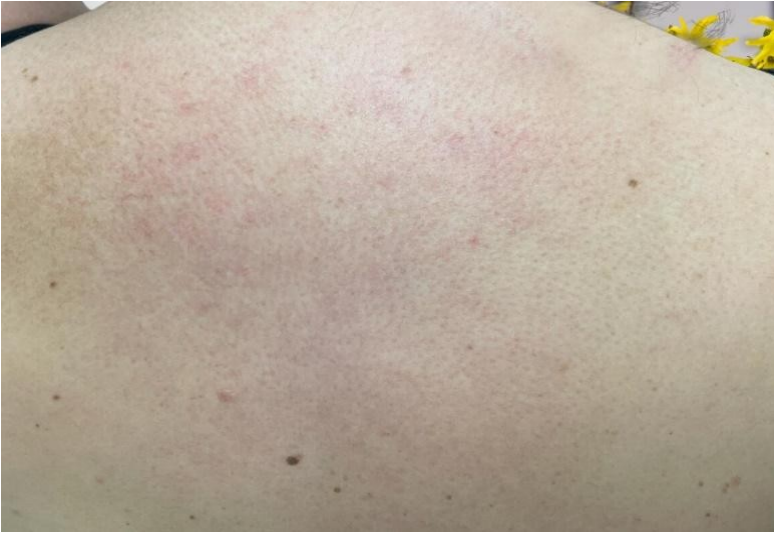1 Month Follow up: The patient reports now reveal that the patient tested positive for anti-MDA5 antibodies. Therefore, cyclosporine, mycophenolate, and steroids were commenced for rapidly progressive ILD. She was followed up after 1 month and had moderate improvement in her muscle weakness. MMT-8 improved a lot, as well as her myalgia, and fatigue. She is able to carry out her daily activities with minimal support; however, her dyspnea and cough remained the same and continues to be her major symptom. Dysphonia and dysphagia have improved but yet not completely normal. Cutaneous rashes have started to heal but were still bothersome. She has no other new complaints.

On examination, all rashes have significantly improved but present, with mild pink rash on the upper chest and upper back. Mild pink non-palpable rash on back of her hands with no ulcerations, but no rash on elbows or knees. periungual erythema has resolved. She does endorse new diffuse alopecia in the last month. Chest examination continues to have bilateral late inspiratory crackle sound in the lung bases upon auscultation without improvement. MMT-8 examination reveals that the patient is able to hold against gravity with mild to moderate pressure in iliopsoas and deltoid, moderate pressure in gluteus medius and maximus, moderate to strong pressure in neck flexor and extensors, but the rest of the systemic examination showed no significant abnormalities.

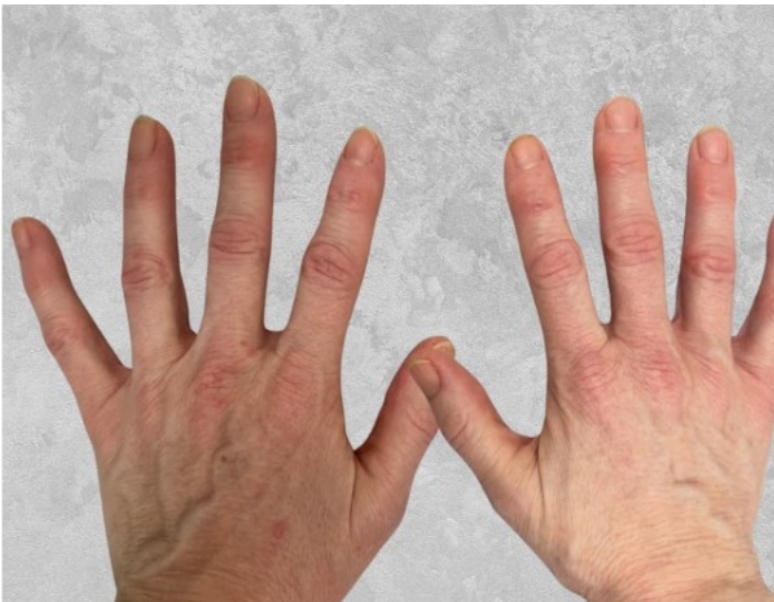Representative Rash Images of Patient:



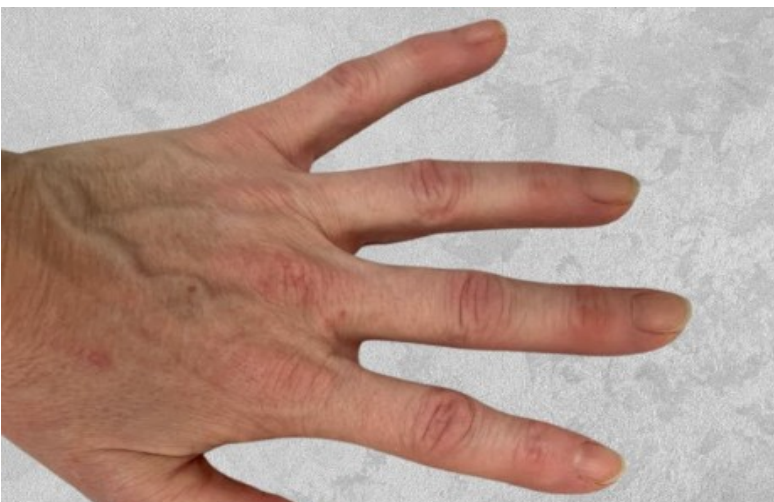Upper chest



Upper back



Dorsum of hand



Periungual changes